


# IN THE NEWS



Summer 2006

## UPCC UPDATE

### PEDIATRIC COIN INGESTIONS

Problem: Between January 2005 and March 2006, the Utah Poison Control Center (UPCC) was involved in the care of 7 children, ages 8 months – 7 years, who swallowed a coin, were initially asymptomatic and subsequently were found to have the coin lodged in their esophagus. This represents a rate of “asymptomatic” esophageal coins of 7%!

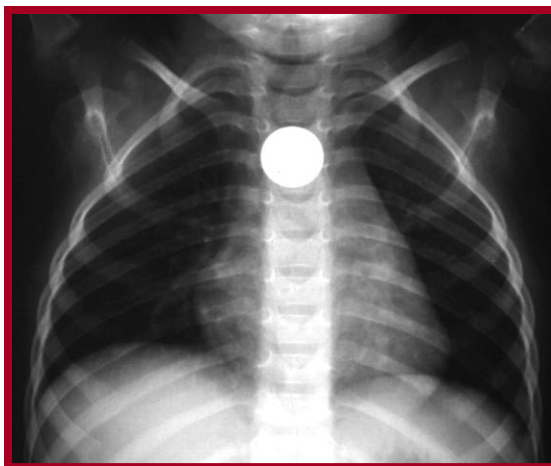


Photo Credit: University of Hawaii School of Medicine

Scope of the Problem: Coins are a common foreign body ingested by children. Coins were involved in 260 (1%) of all exposures reported to the UPCC in children less than 6 years of age in 2005. While the majority of children who swallow coins pass them without problem, a few children who are asymptomatic are eventually found to have the coin lodged in the esophagus. Delayed removal of an esophageal coin entails the risk of anesthesia and perforation.

Solution: All symptomatic pediatric coin ingestions are currently referred **immediately** to the closest emergency department for evaluation. All asymptomatic pediatric coin ingestions are referred to an emergency clinic or emergency department for localization of the coin within 12-24 hours of the ingestion. Coins in the stomach generally pass without problems. No further follow-up from the UPCC will be performed in children who have coins localized in the stomach.

Risk of radiograph? The risk of a single chest x-ray is minimal. The amount of natural radiation we are exposed to in a year is equivalent to approximately 10 chest x-rays.

Utah Poison Control Center  
585 Komas Drive, Suite 200  
Salt Lake City, Utah 84108  
Administrative Line: (801) 587-0600  
Emergency Line: 1-800-222-1222  
Website: [www.utahpoisoncontrol.org](http://www.utahpoisoncontrol.org)

